

Toxoplasma gondii in goats: A Case Report

B. Mihandoost^{1*}, M.S. Fathi Saghezchi¹, Y. Yazdandoost Hamedani¹

¹Department of Clinical Sciences, Faculty of Veterinary Medicine, Shahid Chamran University of Ahvaz, Ahvaz, Iran

*Correspondence:

Author email:
Behrooz.Mihandoost@scu
.ac.ir

Article history:

Received: 12 October 2024
Revised: 10 November 2024
Accepted: 07 December 2024
Published: 17 December 2024

Keywords:

Abortion
Doe
Toxoplasma gondii

Abstract *Toxoplasma gondii* is a zoonotic disease agent with the cats as its definitive hosts; it can infect various animals, including sheep, goats, cattle, and birds. *T. gondii* can cause early embryonic death, resorption, fetal death, mummification, abortion, stillbirth, and neonatal death depending on the stage of gestation. Implementing preventive measures play a significant role in controlling this disease. Six goats from an 80-goat industrial farm were referred to the veterinary clinic at Shahid Chamran University of Ahvaz due to incidents of abortion. In this report, after conducting detailed examinations and tests, the presence of *T. gondii* was confirmed as the sole causative agent of abortion. Under the microscope, cysts of *T. gondii* were clearly observed in brain samples from the aborted fetuses. Since this disease is zoonotic, to prevent infection, humans, especially pregnant women, are advised to avoid contact with suspicious animals and refrain from consuming unpasteurized milk and dairy products (especially goat milk), raw water, and contaminated water with cysts or parasites, as well as raw seafood.



Introduction

Toxoplasma gondii infection is a zoonotic disease whose main host is the cat; it can infect animals such as sheep, goats, cattle, and birds. In addition to milk, *T. gondii* tachyzoites have been experimentally isolated from vaginal secretions, saliva, nasal secretions, and urine of infected goats [1]. The excretion of tachyzoites in the milk of naturally infected goats has been reported [2]. The causative organism has a complex life cycle, involving an asexual cycle that can occur in any species of mammal or bird and a sexual cycle that can only be completed in cats and wild Felidae. In the cat family, the parasite multiplies within the epithelial cells of the intestine, and consequently,

oocysts are excreted in the faeces for about 8 days, during which time tens of thousands of oocysts can be shed. These oocysts sporulate within a few days and are then ingested by sheep [3]. *T. gondii* can cause early embryonic death, resorption, fetal death, mummification, abortion, stillbirth, and neonatal death depending on the stage of gestation. If infection occurs in the first half of pregnancy, symptoms are more severe than those occurring in the second half [4]. Preventive measures include educating farmers, reducing environmental contamination by oocysts, decreasing the population of cats that spread oocysts, limiting cat breeding, and implementing sufficient ongoing programs to control stray cats. *T. gondii* infection is widely

prevalent in humans and animals globally, and it can occur before or after parturition [5]. Results of a recent study revealed burden of *T. gondii* in muscle samples of goats and that even small serving sizes (5 g and 10 g) of meat have the potential for the transmit of *T. gondii* if consumed raw or under-cooked [6]. This study investigates abortion caused by toxoplasmosis in an industrial farm at Agricultural Sciences and Natural Resources University of Khuzestan, Mollasani, Khuzestan, Iran.

Clinical history

On February 17, 2024, a total of six goats from an industrial farm housing 80 goats at Agricultural Sciences and Natural Resources University of Khuzestan, Mollasani, were referred to the veterinary clinic located at Shahid Chamran University of Ahvaz. Upon examination, it was determined that abortions had occurred between days 100 and 150 of pregnancy, with 12 aborted goats, representing 15% of the herd. The general history of the herd, including vaccination and treatment records, was documented, and at the beginning of the work, the absence of brucellosis was confirmed by performing the Rose Bengal screening test. One method to diagnose *Toxoplasma* is by observing tissue cysts, which was conducted as follows. First, the scalp of the fetus was opened and the anterior part of the skull removed using osteotom gouges and a hammer, then the pathological appendages on the brain tissue were examined, but no significant complications were observed, and after that, using a sterile forceps, a part of the brain tissue was separated and spread on a glass slide in robbing mode. After necropsy, smears were prepared from the brain samples of the aborted fetuses and sent to the clinical pathology department for Giemsa staining. Thin smears were stained with 5 % giemsa solution following fixation with methanol. The prepared smears were then examined for the presence of *T. gondii*. More than 30 microscopic fields of 6 films were examined using 100 magnification. According to the reported history, all goats in the herd were fed straw and barley and treated with 20%

oxytetracycline every 15 days. Several stray cats and dogs were present in the area, and no deworming treatment had been administered to the herding dogs or resident cats. Abortions had also been observed in neighboring herds. No specific clinical signs were observed in the herd, and some male goats were kept with the herd. The herd had received only the enterotoxemia vaccine, and there was a history of dietary changes.

Brucellosis-induced abortion was ruled out after a negative Rose Bengal test. The respiratory and heart rates of the goats referred to the veterinary clinic were within the normal range. The goats' body temperature was 38.5°C (within the normal range). Hemogram results indicated that the entire herd suffered from calcium deficiency, and some goats were also affected by anemia and leukopenia (Table 1). Necropsy studies of fetal samples revealed hyperemic and necrotic cotyledons containing purulent hemorrhagic fluid resembling 'frozen strawberries'. The inter-cotyledonary spaces appeared healthy and clear. Aside from the abomasum, which was distended, no other organs exhibited signs of hyperemia, pus, or other pathological lesions. The aborted fetuses did not show clinical signs such as putrefaction (maceration), ascites, skin or skeletal abnormalities, hemorrhage, or mummification. Ultimately, Giemsa staining of the brain samples from the aborted fetuses ultimately showed clear evidence of *T. gondii* cysts (Figures 1 & 2).

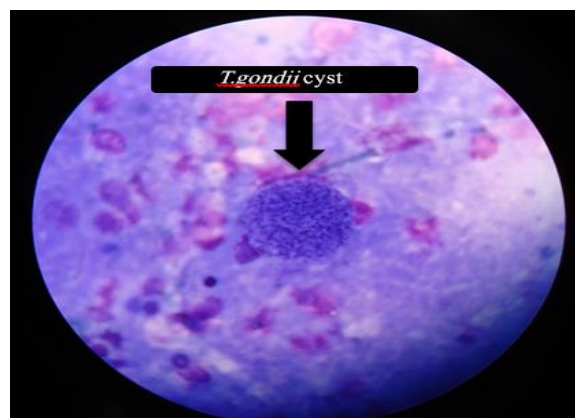
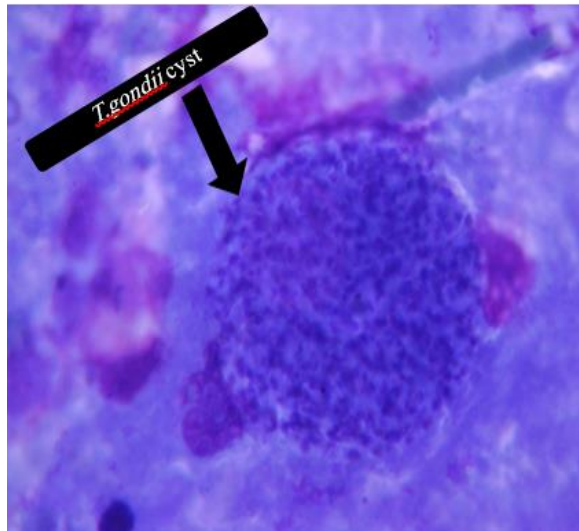


Fig 1. *Toxoplasma gondii* cyst in the examined sample

Table 1. Leukogram, PCV and some macro elements levels in 6 referred does

Parameters	Doe 1	Doe 2	Doe 3	Doe 4	Doe 5	Doe 6
Neut segmented (%)	43	64	52	44	30	30
Lym (%)	52	35	44	57	70	65
Mon (%)	3	3	1	3	4	2
EOS (%)	2	1	1	5	2	4
Ca (mg/dl)	8.58	8.62	9.01	9.49	8.47	8.80
P (mg/dl)	5.34	6.84	7.19	6.33	7.52	5.49
PCV (%)	29	32	33	23	27	31

**Fig 2.** *Toxoplasma gondii* cyst in the examined sample

Discussion

Tests and examinations of the herd and aborted fetuses identified *T. gondii* as the cause of abortion. *T. gondii* infection can cause abortion and fetal death, resulting in significant economic losses for the herd [4]. This zoonotic disease has led to strict recommendations for preventing human infection, particularly advising pregnant women to avoid contact with suspected animals and refrain from consuming unpasteurized milk and dairy products (especially goat milk), untreated or contaminated water containing cysts or parasites, and raw seafood [5]. Necessary recommendations for controlling this disease include disinfecting the herd's bedding, controlling and castration male cats around the farm, and isolating the infected herd from other farm herds [7]. Unfortunately, there is no definitive treatment for this disease, although adding monensin supplements to the feedstuff can slightly prevent abortions [8]. Therefore, it is

recommended that the farm manager prescribe monensin and castrate the cats.

Conflict of interest

The authors declare that they have no competing interests.

Ethical approval

This research was conducted in accordance with the relevant international standards.

Reference

1. Dubey JP. Persistence of encysted *Toxoplasma gondii* in caprine livers and public health significance of toxoplasmosis in goats. 1981.
2. Chiari CA, Neves DP. Toxoplasmose humana adquirida através da ingestão de leite de cabra. Mem Inst Oswaldo Cruz. 1984; 79.
3. Noakes DE, Parkinson TJ, England GCW. Veterinary Reproduction and Obstetrics. 10th ed. British Library; 2019.
4. Dubey JP. Toxoplasmosis—an overview. Southeast Asian J Trop Med Public Health. 1991; 22:88–92.
5. Abu DMA, Ababneh MM, Giadinis ND, Lafi SHQ. Ovine and caprine toxoplasmosis (*Toxoplasma gondii*). 2010.
6. Dubey JP, Murata FHA, Cerqueira-Cézar CK, Kwok OCH. Public health and economic importance of *Toxoplasma gondii* infections in goats: The last decade. 2020.
7. Buxton D. Ovine toxoplasmosis: a review. J R Soc Med. 1990; 83:509–11.
8. Buxton D, Finlayson J. Experimental infection of pregnant sheep with *Toxoplasma gondii*: pathological and immunological observations on the placenta and foetus. J Comp Pathol. 1986; 96:319–33.

How to cite this article:

Mihandoost, B., Fathi Saghezchi, M.S., Yazdandoost Hamedani, Y. *Toxoplasma gondii* in goats: A Case Report. *Veterinary and Comparative Biomedical Research*, 2025, 2(1): 16 – 18.
<http://doi.org/10.22103/Vcbr.2024.24360.1029>